

**Histopathology of X-ray effects on renal tissue of *rattus rattus* var. *albinus* fed with a *triticum aestivum* (wheat)- heavy diet****Histopatología del efecto de los rayos X en tejido renal de *rattus rattus* var. *albinus* con una dieta reforzada con *triticum aestivum* (trigo)**RODRÍGUEZ VEGA, Juan Luis<sup>15</sup>; MEJÍA PINEDO, Davis Albert<sup>16</sup>; COAGUILA CUSICANQUI, Luis Ángel<sup>17</sup>; CALDERÓN MUNDACA, Wilmer Leoncio<sup>18</sup>; ZAMORA ROMERO, Pedro<sup>19</sup>**Abstract**

The purpose of this research was to determine the effect of X-rays on the gastric mucosa in *Rattus Rattus* var. *Albinus* with *Triticum Aestivum* (wheat)-heavy diet. Twenty-four albino, adult male rats weighing between 200 and 250 g were used, which were randomly distributed into two groups: control and experimental, with 12 animals each. Control group was randomly subdivided into 2 subgroups, group D: which did not receive wheat and was not irradiated, and B: which did not receive wheat but was irradiated. Experimental group was randomly subdivided into 2 subgroups, group C: which received wheat and was not irradiated and A: which received wheat and was irradiated. Oral administration of wheat was performed during 16 previous days to X-ray irradiation, 18 mSv, the animals were housed in cages, anesthetized with 0.6% of pentobarbital in doses of 0.5 ml / kg p.c., v.i.p and then taken to X-rays room in the center of ESSALUD - El Porvenir - La Libertad and there was a radiation shot. It concludes that the diet with *Triticum aestivum* (wheat) avoids the cellular damage of X radiation, in the esophagus of *Rattus rattus* var. *Albinus*.

**Key words:** *Triticum aestivum*, Xray, esophagus, *Rattus rattus* var. *Albinus*

**Resumen**

La finalidad de la presente investigación fue determinar el efecto de los rayos X sobre la mucosa gástrica en *Rattus Rattus* var. *Albinus* con una dieta reforzada con *Triticum Aestivum* (trigo). Se utilizaron 24 ratas albinas, machos adultos, con pesos entre 200 a 250 g, los cuales fueron distribuidos al azar en 2 grupos: control y experimental, con 12 animales cada uno. El grupo control fue subdividido al azar en 2 subgrupos, el D: que no recibió trigo y no fue irradiado, y el B: que no recibió trigo pero fue irradiado. El grupo Experimental fue subdividido al azar en 2 subgrupos, el C: que recibió trigo y no fue irradiado y el A: que recibió trigo y si fue irradiado. La administración oral de trigo se realizó durante 16 días previos a la irradiación con Rayos X, 18 mSv, los animales fueron alojados en jaulas, anestesiados con pentobarbital al 0,6% en dosis de 0,5 ml/kg p.c, v.i.p y luego llevados a la Sala de Rayos X en el Centro de ESSALUD - El Porvenir - La Libertad y se dio un disparo de radiación. Se concluye que la dieta con *Triticum aestivum* (trigo) evita el daño celular de las radiaciones X, en el esófago de *Rattus rattus* var. *Albinus*.

**Palabras clave:** *Triticum aestivum*, Rayos X, esófago, *Rattus rattus* var. *Albinus*

**Received:** May 06, 2016

**Accepted:** June 10, 2016

**Published:** August, 2016

---

<sup>15</sup> Dr. in Sciences, Master in Academic Teaching and Research, Microbiologist.

<sup>16</sup> Master's Degree in Medical Sciences Physiology and Biophysics, Pharmaceutical Chemist.

<sup>17</sup> Biologist, specialist in Microbiology, Biochemistry and Microbiology Teacher

<sup>18</sup> Master in Physiology, Specialist in Intensive Care Medicine, Director of the School of Human Medicine

<sup>19</sup> Biologist, Researcher, Professor.

## Introduction

The objective of this research was to determine the histopathological configuration in gastric cells of *Rattus rattus var. X-ray irradiated Albinus* fed with a *triticum aestivum* (wheat)- heavy diet.

Wheat is one of the three most produced grains globally, like corn and rice, and the most consumed by man in the western civilization for a long time. Wheat grain is used to prepare flour, semolina, whole meal flour, beer and a variety of food products.

Within the wheat grain, the part that contains most food properties is the germ, which constitutes 2.5 or 3% of total weight of the grain, where are most concentrated the vitamins, minerals, proteins and oils. The cell membrane protectors act as stabilizers of the cell wall and the skin, in this way the mucous and the teguments are protected of the X radiation and free radicals, obtaining also a recovery of the cells already injured.

The Double Survival Study with radiation and chemotherapy plus surgery for stomach cancer rates, says Dr. Smalley with the other studies did not demonstrate a significant benefit for therapy on the part of standard surgical resection.

"This research carried out by groups of clinical trials in the United States and Canada, is the first great study to find a combination of treatments that substantially and significantly improves the recovery of this illness", says Dr. Smalley, "now that we have gone a big step forward, we expect to advance quickly in the improvement of the attention of these patients".

Stomach cancer is the second cause of death from cancer in the world, it is expected to kill more than 630,000 people throughout the

world this year. According to the study: Mediterranean Diet related with a lower risk of stomach cancer, it was evaluated the association between the Mediterranean diet and relative gastric adenocarcinoma related to the anatomical location (cardia and noncardias) and the histological types (diffuse and intestinal). To control the measurement error in dietary, a calibration study was performed on a subsample.

During a follow-up of 8, 9 years, there were 449 recognized cases of incident gastric adenocarcinoma that could be analyzed. In comparison with a low adherence relative Mediterranean diet, high adherence was associated with a significant decrease in the risk of gastric adenocarcinoma (hazard ratio (HR), 0.67, 95% confidence interval (CI), 0.47 to 0.94), after stratification by the centre, age and after adjustment for known cancer risk factors.

Garlic protects against some types of cancer, "Many scientists believe that garlic helps to prevent stomach cancer because it has antibacterial effects against a bacterium, *Helicobacter pylori*, which is in the stomach and is known to promote cancer there".

Despite the decrease incidence in western countries, the care of gastric cancer remains a concern, considering that many patients are diagnosed with an advanced disease. Considering that localized gastric cancer has benefited from advances in surgical treatment and perioperative chemotherapy, patients with unresectable or metastatic state get a negative diagnosis.

However, advances in chemotherapy have arisen with the appearance of the most convenient schedules and active of treatment, but no significant advance has been made in terms of survival.

Recent medical test in advanced gastric cancer have focused on targeted therapies.

Numerous circumstances, physiological or pathological, can increase free radical production, a free radical is any atom or capable molecule of independent existence, which possesses in its outer electronic layer an unpaired electron.

As a consequence, they are substances with great capacity to react with nearby molecules, which can cause chemical and structural changes that manage to be translated in the loss of their function and, so, increase oxidative stress. Among them there are X-radiations to which we are exposed with greater or less intensity in any moment of our lives.

The effects produced for these radiations are classified in: Deterministic effects, which effects are related with the dose and is necessary a threshold value. Also, they are consequence of external or internal overexposure, instantaneous or prolonged overall or part of the body, causing the death of a quantity cells that cannot be fully compensated for by the viable cells proliferation. The resulting loss of cells can cause severe deterioration of the organ function or tissue, clinically detectable.

Study of the deterministic effects about the body consists in the analysis of the Spatial and Temporal distribution of doses, it is possible to have an approximate idea of them, considering situations in which the whole body receives radiation in a very short time (seconds, minutes or hours). However, if the same dose was distributed over the years, its effects would be much less aggressive. Radiation to 3 Sv, the gastrointestinal symptoms are severe, there is fatigue, in severe cases diarrhea and fever.

With ups and downs in the general state, over weeks or months, the person should watch out for infections and dehydration. Normally, it recovers within weeks or months, with a risk to life, although low, of 4 to 6 Sv; there is significant damage to the intestinal mucous membrane and bone marrow. Risk to life. For doses in the range of 6 Sv, the intensive medical care is essential, for more than 6 Sv; there is a high probability of death within a few weeks. For doses of 10 Sv the damage to the intestinal mucosa is so complete and incurable that it leads to an intolerable dehydration after two weeks. For 50 Sv the central nervous system is damaged, producing the loss of consciousness in hours and death in days. The progressive increase in this type of alterations in the last decades has caused a great health and social concern, whereby all aspects of photoprotection are research object from various points of view: physical, chemical, biological and health. For all the exposed the following problem was raised:

Will the gastric radiation have an effect with X-ray on *Rattus rattus var. albinus* with a heavy diet of *Triticum aestivum* (wheat)? For which it was postulated that *Triticum aestivum* has a protective effect of radiation in gastric cells of *Rattus rattus var.*

## Method

**Food preparation:** *Triticum aestivum* was obtained from Otuzco province and classified in the *Herbarium Truxillensis* of the National University of Trujillo. There were weighed 30 g of wheat as a unique daily ration, for animals with ad libitum water.

**Distribution of groups:** 24 specimens, six months old represented the total group. Weighing between 200 - 250 grams for 16

days before the irradiation, each animal was kept in separate cages, receiving feed once a day 30 g, as appropriate, the cages were conditioned with tiles for the animals to pick up and use all of the feed provided. Then they were divided into two groups: **Control Group** integrated for 12 animals that consumed a normal diet of Biotherium of the Faculty of Pharmacy and Biochemistry, consisting of 10 grams of barley and corn, which was divided into two subgroups. Subgroup D, with 6 animals that were not subjected to radiation X. and subgroup B, with 6 animals that were subjected to radiation X.

**Experimental group:** Integrated by 12 animals, that were fed with 10 grams of raw wheat, and they were subdivided into two sub-groups: Subgroup A, with 6 animals that were subjected to X-radiation, and subgroup C, with 6 animals that were not subjected to X-radiation.

**Radiation of the species:** On the 16th day after the start of feeding with *Triticum aestivum*, the 24 animals were subjected to a radiation dose of 18 m Sv, with the WATSON X-ray equipment, at the ES-SALUD centre. El Porvenir.

After the reinforcing for 10 days the feeding with wheat to two groups and with food from Biotherio to the other two, the radiation proceeded again, 10 days after, the same procedure was performed. Previously, they were immobilized with pentobarbital 0.6% in saline solution, at a dose of 0.5 ml/kg body weight for intraperitoneal route.

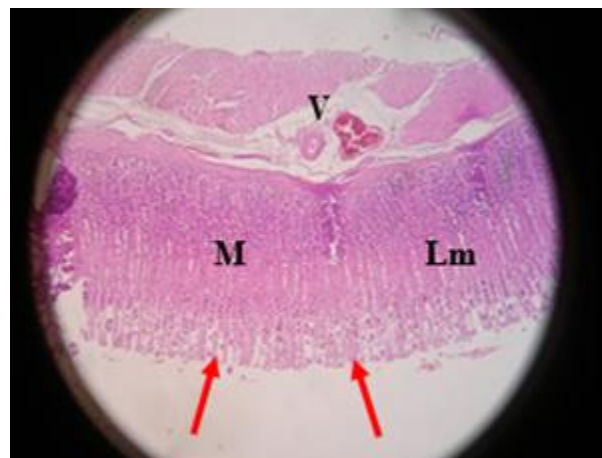
**Slaughter of the species:** After radiation, the 24 animals were slaughtered, their stomachs removed, and they were preserved in 10% formalin.

**Histopathological study:** Longitudinal and transverse cuts of extracted esophageal tissue were made, staining of the tissue cuts were made with hematoxylin-eosin.

## Results

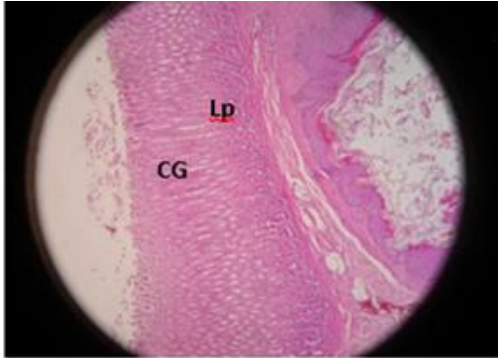


**Figure 1.** Researcher (Dr. Rodríguez Vega Juan Luis) with the batch of rats to be evaluated by histopathology.

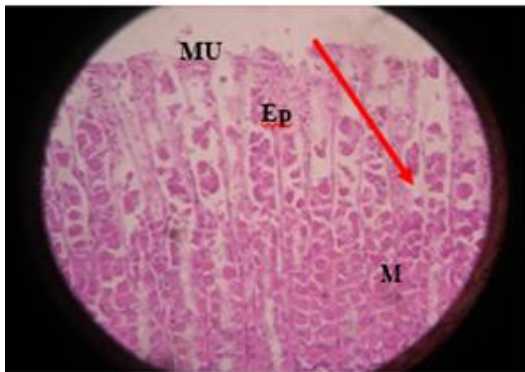


**Figure 2.** Stomach of rats not irradiated without wheat. Fundic part of the stomach. Gastric mucosa showing gastric foveolar

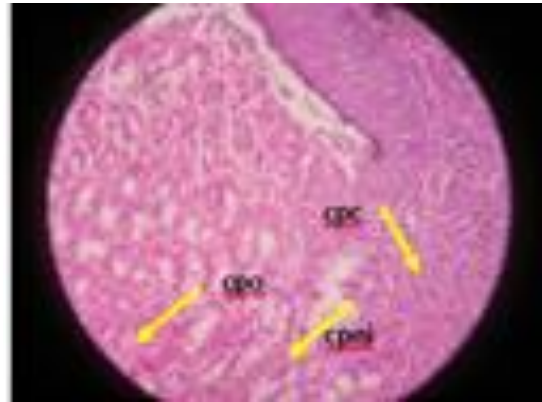
(arrows). Dense storage in mucous cells (m). Muscularis mucosae (mm) and the submucosa rich in vessels (v). It corresponds to a normal histological cut. H&E (x100).



**Figure 3.** Stomach of rats not irradiated without wheat Stomach. Detail of the fundic part. it looks the entrance openings of the foveolar coated with high prismatic epithelium monostratified (ep). Abundant mucous cells with dense storage (m). Mucina on the surface (mu). H&E (x400) Normal Histology.

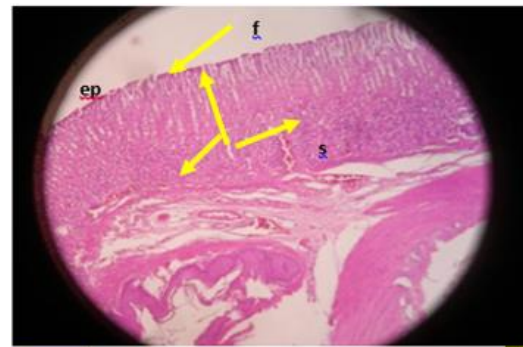


**Figure 4.** Stomach of rats not irradiated without wheat. Stomach Rat. Left: Mucosa of the gastric body region (GB), irregular numeric arrangement inside the gastric glands (\*). Narrow band of muscularis mucosae (mm). Abundant cellularity of the lamina propria (lp), findings that confer a normal histology. H&E (x100).



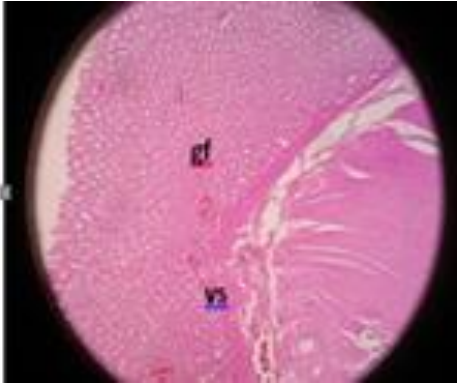
**Figure 5.** Stomach rats not irradiated without wheat.

Stomach Rat. Abrupt transition to gastric epithelium (\*). Center: gastric epithelium (GE) fundic part characterized by the fundic glands with presence of mucous cells (mc), oxyntic parietal cells (opc) and cymogenic principals cells (cpc). findings that confer a normal histology. H&E (x400).



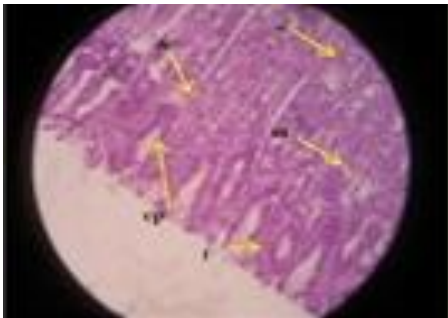
**Figure 6.** Stomach rats irradiated without wheat.

Stomach Rat. Upper: Gastric mucosa showing the surface of the epithelium with loss of microvilli (ep), few open foveolar (f). Presence of dilated blood vessels (bv), due to radioactive irritation. H&E (x100).



**Figure 7.** Stomach rats irradiated without wheat.

Stomach Rat. Gastric mucosa with loss of glands and open foveolar (gf). Presence of dilated blood vessels in the fundus (bv), which obeys irradiation and in response to angiogenesis. H&E (x100).



**Figure 8.** Stomach rats irradiated with wheat

Stomach Rat. Detail gastric mucosa showing the entrances of the foveolar (f) covered by a high mono-stratified prismatic epithelium (ep). Fused glands with presence of oxyntic parietal cells (&) and cymogenic principals cells (#). Low presence of mucous cells (m). H&E (x400) Radiation will most likely cause injury to mucous cells.



**Figure 9.** Researcher (QF. Mejía Pinedo Davis) separating the batch to give the test ration.



**Figure 10.** Researcher (Lic. Calderón Mundaca Wilmer Leoncio ) reading the lamina obtained post mortem.

## Discussion

Ionizing radiations are physical agents found naturally in the environment, although they can be a product of human activity generated in obtaining nuclear energy and its application in medicine for diagnosis and treatment. Ionizing radiation is a risk factor

for cancer and also dietary habits since young age, it has a cumulative effect of carcinogens or lack of intake of protective substances against cancer in the nutrition. There is convincing evidence about the increased risk of stomach cancer, overweight and obesity as well as the consumption of very strong beverages and foods (13). In the histopathological examination of the rat not irradiated without wheat. In Stomach Fundic mucosa they show open gastric foveolar, normal skeletal, dense storage in mucous cells, lamina muscular and the submucosa rich in vessels. Muscularis mucosae and the submucosa rich in vessels. Corresponds to a normal histological section (Figure 2). It is also observed the detail of the fundic area, open entrances of the foveolar coated with high prismatic epithelium simple, abundant mucous cells with dense storage, mucin on the surface and normal histology (Figure 3). The animals that received irradiation with X-rays, fed with diet of Bioterio. In the stomach superior: gastric mucosa shows the surface of the epithelium with loss of microvilli, few open foveolar. Presence of dilated blood vessels, which is due to radioactive irritation. (Figure 7).

The cellular damage produced by the reactive oxygen species occurs on different macromolecules such as lipids: where greater damage is produced by free radicals, since it affects structures rich in polyunsaturated fatty acids, altering the cellular permeability, producing edema and cell death. Lipid peroxidation represents a form of tissue damage that can be triggered by oxygen, superoxide anion, hydrogen peroxide and the hydroxyl radical which is the most harmful. Fatty acids are components of cell membranes, it is important for normal functioning such as cell regeneration and reproduction. Once this process starts, it takes the form of a waterfall, with the production of

free radicals that leads to formation of organic peroxides and other products like unsaturated acids. Once formed, these free radicals are responsible for the cytotoxic effects (14). In what corresponds to the animals that were not irradiated and were fed with wheat, the stomach of the left area: Mucosa of the gastric body region, irregular numerical arrangement inside the gastric glands, and a narrow band of muscularis mucosae. Abundant cellularity of the lamina propria, findings that give it a normal histology. (Figure 4). It also the stomach has an abrupt transition to gastric epithelium. Center: gastric epithelium (GE) fundic zone characterized by the fundic glands with the presence of mucous cells, oxyntic parietal cells and cyanogen main cells. This discovery is given a normal histology. (Figure 5). Finally, in the animals that were irradiated and fed with wheat. The rat stomach details the gastric mucosa showing the foveolar entries covered by a high prismatic epithelium simple. Fundic glands with oxyntic parietal cells and cymogenic main cells. Lack of mucous cells (figure 8). These results, which show the tissue of the stomach cells was preserved, in animals fed *Triticum aestivum*, it has Vitamin E, probably due to acts at the level of stability and integrity of the biological membranes, protecting their unsaturated lipids against the aggressions of free radicals in nerves, muscles, circulatory and immune systems. Whose assimilation depends on the amount of grease of the food ingested and the adequate pancreatic and biliary functioning; also its absorption is facilitated by selenium. Fruits and vegetables can make a difference in diet, because they contain carotenoids, folate, Vitamin C, minerals, fiber, other photochemicals such as dithiols, glucosinolates, indoles, isothiocyanates, flavonoids, phenols, protease inhibitors, isoflavones (13). Action

mechanisms of nutrients to prevent cancer would be: Its behavior as antioxidants, modulation of detoxification enzymes, inhibition of the production of nitrogen products such as nitrosamines, DNA methylation, modulation of hormone metabolism, antibacterial action, stimulation of the immune system (13).

Primary prevention, with emphasis on the management of lifestyle-related factors at all ages and interventions to combat environmental carcinogens and occupational, can bring good results in reducing cancer, in regard the World Health Organization (WHO), it is estimated that until to 2.7 million lives could be saved of dying from cancer each year in the world if the consumption of fruits, legumes and vegetables were adequate. Foods consumed daily replace foods with high concentrations of saturated fats, sugar and salt, and strengthen the living organism with protective components such as carotenoids, antioxidant vitamins, phenolic compounds, terpenoids, steroids, indoles and fibers (13). Also, the wheat diet would be contributing to the cellular stability of the membranes protecting them from damage facing type X irradiation.

## Conclusions

It is concluded that the diet with *Triticum aestivum* prevents cellular damage from X-radiation in *Rattus rattus* var. albinus cells so it has a cytoprotective effect.

## Bibliographic references

Astro P, La Radioterapia para el Tratamiento. RTAnswers [Internet]. [acceso 6 de marzo de 2016]. Retrieved from: <http://www.rtanswers.org/downloads/spanish/rtforcancersp.pdf>

Bellorín M, Fernández J. Alteraciones cromosómicas en linfocitos humanos inducidas por rayos X. SCIELO. [Internet]. 2002. [acceso 7 de marzo de 2016]. Retrieved from: [http://www.scielo.org.ve/scielo.php?pid=S0535-51332002000300003&script=sci\\_arttext](http://www.scielo.org.ve/scielo.php?pid=S0535-51332002000300003&script=sci_arttext)

Cárdenas J, Bajetta E, Bussoni R. Enteropatía Iatrogena por Radioterapia y Quimioterapia. [Internet]. [acceso 2 de marzo de 2016]. Retrieved from: <http://incan.org.mx/revistaincan/elementos/documentosPortada/1241744669.pdf>

Crespo G, Gutiérrez Q. Antioxidantes. Herbogeminis [Internet] 2009. Acceso 5 de marzo de 2016]. Retrieved from: <http://www.herbogeminis.com/antioxidantes.html>

Fernández C. Daños biológicos por radiación. Pr [Internet]. [Acceso 08 de marzo del 2016]. Retrieved from: [http://www.cab.cnea.gov.ar/divulgacion/seresvivos/m\\_serresvivos\\_f9.html](http://www.cab.cnea.gov.ar/divulgacion/seresvivos/m_serresvivos_f9.html)

Gil Cebrián J, Martínez García P, Díaz Torres I, López Alvaro J. Lesiones por Radiaciones ionizantes. UNI Net. [Internet]. [Acceso 07 de marzo del 2016] Retrieved from: <http://www.cancer.org/Espanol/cancer/Queesloquecausaelcancer/Otrosagentescancerigenos/la-exposicion-a-la-radiacion-y-el-cancer>

Gil Cebrián J, Martínez García P, Díaz Torres I, López Alvaro J. Lesiones por Radiaciones ionizantes. UNI Net. [Internet]. [Acceso 8 de marzo del 2016] Retrieved from: <http://tratado.uninet.edu/c0901i.html>

Lamelo F, García M, Charlín G, Fernández O. Efectos secundarios del Tratamiento Oncológico. Guías clínicas [Internet] 2006.



[acceso 9 de marzo de 2016]. Retrieved from:  
[http://www.fisterra.com/guias2/PDF/e\\_cancer.pdf](http://www.fisterra.com/guias2/PDF/e_cancer.pdf)

Leonore A. Estudio de ajo Espectáculos protege contra algunos tipos de cáncer. Perú: Rev. Medscape Medical News. [Revista en internet] 2010 [acceso 12 de marzo del 2016]. Retrieved from:  
<http://www.medscape.com/viewarticle/412174>

Martínez B. Plantas Medicinales. Botánica [Internet] 1999. [Acceso 3 de marzo del 2016]. Retrieved from:  
<http://www.botanical-online.com/botanica2.htm>

Murillo M, Valentín V, Valentín M. Síntomas Asociados al Tratamiento con Radioterapia. Psicooncología [Internet] 2004 octubre. [acceso 12 de marzo de 2016]. Retrieved from:  
<http://revistas.ucm.es/psi/16967240/articulos/PSIC0404120151A.PDF>

Patrick D. Evolución de los estándares de atención en el cáncer gástrico avanzado: Rev. Medscape Medical News. [Revista en internet] 2010 [acceso 10 de marzo del 2016]. Retrieved from:  
<http://www.medscape.com/viewarticle/754570>

Portillo I, Fernández-Corada A, García M. Efectos Secundarios del Tratamiento en el Paciente Oncológico. Boletín Farmacoterapéutico de Castilla-La Mancha [Internet] 2006. [acceso 5 de marzo del 2016].

Salas C, Carlos R. [Internet]. [Acceso 07 de marzo del 2016] Source:  
[http://www.lukor.com/ciencia/radicales\\_libres.htm](http://www.lukor.com/ciencia/radicales_libres.htm)

Stephen E. Dieta mediterránea relacionado con un menor riesgo de cáncer de estómago. Perú: Rev. Medscape Medical News. [Revista en internet] 2011 [acceso 11 de marzo del 2016]. Source:  
<http://www.medscape.com/viewarticle/714369>

Stephen E. Supervivencia dobles con radiación y quimioterapia más cirugía para el cáncer de estómago tarifas. Perú: Rev. Medscape Medical News. [Revista en internet] 2011 [acceso 10 de marzo del 2016]. Source:  
<http://www.medscape.com/viewarticle/412171>